

A Survey on Abnormal Conformation of Horses in Patna District of Bihar

MK SINGH*, NK SINGH, GD SINGH, R TIWARI AND A KUMAR



ARTICLE INFO

Received on : 26-04-2019
Accepted on : 28-06-2019
Published online : 01-09-2019

ABSTRACT

A total of 90 horses were screened in the equine survey which included stud of Bihar military police, horses registered for treatment at the clinical complex of Bihar veterinary college Patna and at different veterinary hospitals and villages nearby Patna. Abnormal conformation in the forelimb and hind limb were recorded. The abnormal conformations were detected on the basis of outline of muscles, physical appearance and structures of bones of a horse. The horses were observed from poll to tail and down to gaskin for alignment of the vertebral column, straightness and symmetry. Abnormal conformation was assessed by viewing the horse from the left side and assessing balance by comparing the head, neck and forelimb with the hind limb and croup. Out of 90 horses screened during the survey, eleven horses were detected with abnormal conformation, which was two toe-out, one toe-in, seven cow-hock and one bow leg. The bad conformations in forelimb were toe-out and toe-in. In toe-out base narrow condition was observed and toes were pointed away from each other which are one of the worst conformations of the forelimb. In toe-in condition, toes were pointed towards one another accompanied by the base narrow condition. The most common abnormal hind limb conformations were cow-hock and bow-leg. In cow-hock, the horses were base narrow up to hock and base-wide from hock downwards whereas in bowlegs the line drawn from *tuber ischii* did not bisect the legs.

KEYWORDS

Toe-in, toe-out, cow-hock, bow-leg, horse, abnormal, conformation

INTRODUCTION

Conformation mentions the physical appearance and outline of a horse as dictated primarily by bone and muscle structures (Mawdsley,1996). To develop an appreciation of lameness and gait defects, it is important to have an understanding of conformation and movement. The present study was carried out to record the prevalence of lameness due to the abnormal conformation of forelimb and hind limb. A judging technique was also prepared for confirmation of good and healthy horses for riding, policing, sports and other purposes. Keeping in mind the importance of abnormal conformation, the present study was visualized to relate the conformational evaluation as a measure to eliminate lameness through responsible breeding in horses.

MATERIALS AND METHODS

In the present study, the survey was carried at different location in and nearby Patna districts of Bihar. The locations were the stud of Bihar Military Police, horses registered for treatment at the clinical complex of Bihar Veterinary College, Patna, Bihar and at different veterinary hospitals and villages in and around 10 Km area of Patna. Ninety horses were screened, out of which four types of abnormal conformation were recorded in eleven horses. The horses were observed from poll to tail and down to the gaskin and the attachments of the appendicular skeleton (limbs) to the axial skeleton (head and trunk) were observed and limb angles were evaluated. The hooves and limbs were evaluated from the front for straightness and symmetry. The tail, straightness and symmetry of the back, the croup, and the point of hip and buttock were evaluated directly from behind. Observations were made slowly from poll to tail for evaluating back muscling, alignment of the vertebral column and left to right symmetry as the forelimb supports approximately 60 to 65% of the horse's body weight and hind limbs are the source of power for propulsion and stopping.

RESULTS AND DISCUSSION

Out of 11 horses having abnormal conformation, the forelimb of two horses was having toe-out abnormal conformation. This conformation was noticed by viewing horse from the front side. In this conformation, toes were pointed away from one another and base narrow condition was observed which was one of the worst conformations of the forelimb. This finding validates the findings of Adams (1974), which suggested that the limb might be crooked as high as its origin at the chest or as low as the fetlock down. It was usually accompanied by base-narrow conformation but rarely was present when the horses were base-wide. In



Fig 1: Toe-out abnormal conformation in the forelimb of horse

Bihar Veterinary College, Bihar Animal Sciences University Patna, Bihar, India

*Corresponding author email: manojsighana@gmail.com

base narrow conformation, the distance between the center lines of the feet at their placement on the ground was less than the distance between the center lines of the forelimbs (Fig. 1).

Another abnormal conformation detected was a toe in. It was present in one out of eleven horses having abnormal conformation. The horses when viewed from the front had

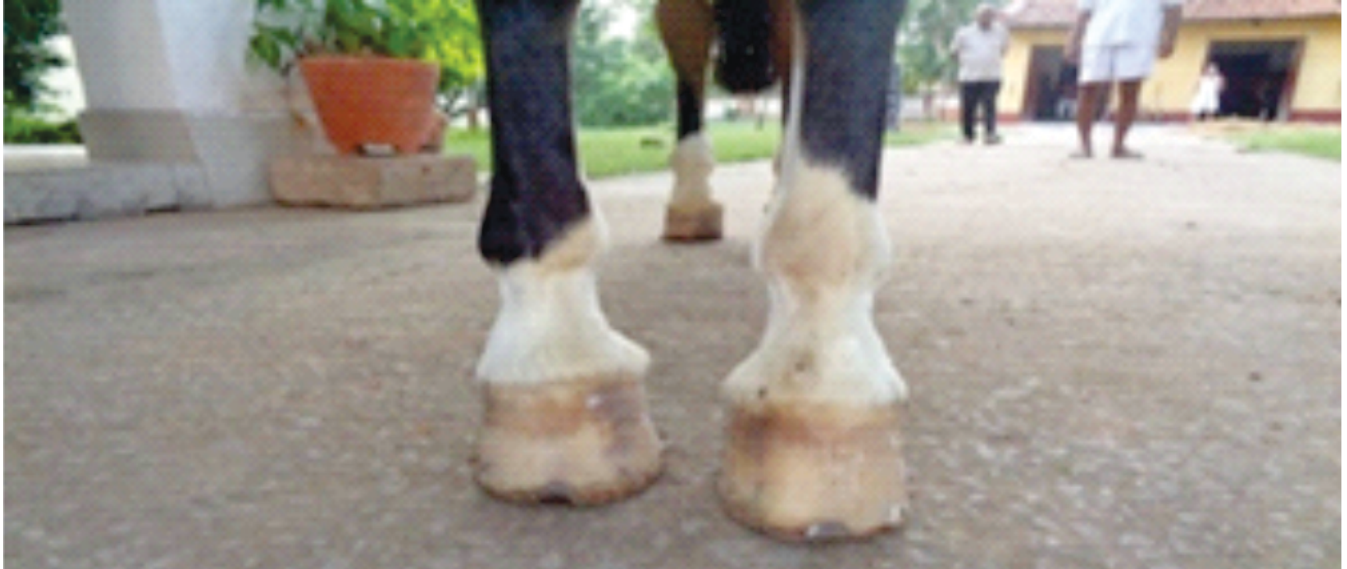

Fig 2: Toe-in abnormal conformation in Forelimb Of horse

Normal hind limb conformation was inspected by dropping a line from the point of the buttock (*tuber ischi*) to bisect the limb as per Dalin *et al.*, (1985). In the present survey, the most common abnormal hind limb conformation noticed was cow hock, which was recorded in seven out of eleven horses having abnormal conformation. The horses were usually base narrow as far as the hock and base-wide from the hocks down. In these horses, the hock joint appeared to be in excessive

stress on movement and showed swelling on hock joint, which resembled symptoms similar to bone spavin. These horses showed difficulty in trotting and such type of abnormal conformation was recorded to be one of the worst hind limb conformations in which the horses were not fit for racing. These findings were in accordance with the observations of Beeman (1983); (Fig.3).

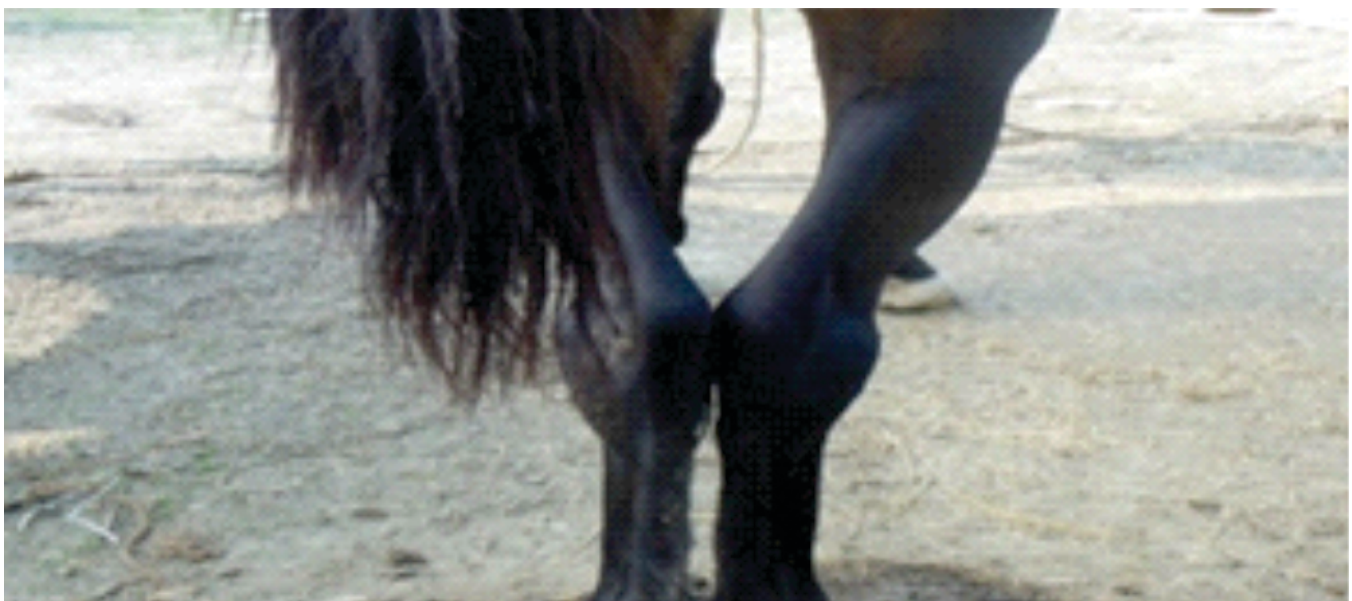


Fig 3: Cow hock abnormal conformation in hind limb of horse

In the present survey, another hind limb abnormal conformation observed in one out of eleven horses was bowleg in which the horse was viewed from the front after dropping a line from the point of the buttock (tuber ischii) and

it was observed that it did not bisect the limb. These horses were base wide as far as hocks and base narrow from hocks down. These findings collaborate with the observations of [Halmstrom *et al.*, \(1995\); \(Fig 4\).](#)



Fig 4: Bowleg abnormal conformation in hind limb of horse

REFERENCES

- Adams OR.1974. Lameness in horses.3rded.Philadelphia: Lea & Febiger.
- Beeman GM. 1983. Correlation of defects in conformation to pathology in the horse. *Proc AM Assoc Equin pract.* **19**: 177.
- Dalin G, Magnuson LE and Thafvelin BC.1985. Retrospective study of hind quarter asymmetry in standardbred trotter and its correlation with performance.*Equine Vet. J.***17**:292-296.
- Halmstrom M, Magnuson LE and Philipssen J.1995. Variations in conformation of Swedish Warmblood horses and conformational characteristics of elite sport horses. *Equine Vet.J.* **22**:186-193.
- Mawdsley A, Kelly EPand Smith FH. 1996. Linear assessment of the Thoroughbred horse: An approach to conformation evaluation. *Equine Vet. J.***28**:461-467.

Citation:

Singh MK, Singh NK, Singh GD, Tiwari R and Kumar A. 2019. A survey on abnormal conformation of horses in Patna District of Bihar. *Journal of AgriSearch* **6** (3): 128-130